

COLORECTAL CARCINOGENESIS - EXPERIMENTAL STUDY

Mircea Sandor, Ovidiu Pop, Anca Huniadi, Rodica Negrean

University of Oradea, Faculty of Medicine and Pharmacy, University street, 1 no., Oradea,
drims75@yahoo.com

Abstract

The objectives of the investigation were assessment and confirm the value of colorectal carcinogenesis model. The result, in this experimental model, show that tumor induction with DMH for a period of only 12 weeks and under the conditions described, to satisfy the claim for the production of colo-rectal epithelial tumors, benign and malignant conditions of homogeneity the frequency and distribution of their metastatic.

Key words: colorectal cancer, carcinogenesis, experimental anastomosis

INTRODUCTION

The objective of the investigation was to study and to demonstrate the value of a colorectal carcinogenesis model, preliminary study. Validation experiment was based on a uniform methodology for tumor induction to reproduce the colorectal tumors and to create an anastomosis "tissues" viable. According to the study, we determined some parameters and used the following tests: Media and change tests that samples showing differences in mean and / or variations in results were considered statistically significant for p value <0.05.

MATERIAL AND METHODS

We used 15 Wistar rats, of both sexes, approximately eight weeks, and weighing between 160 and 200 grams, which were kept in a controlled environment as the humidity, temperature and cycles of light / dark without restricted food (commercial diet "standard") or liquid (water).

To induce tumors a carcinogenic agent DMH-dimethyl (Merck) was administered to each mouse for 12 weeks, (Fig 1) by weekly subcutaneous injections of 20 mg / kg, after which we sacrificed the animals and examined a sample of the great bowel of these animals after autopsy. DMH was prepared in the following way: to weigh the chemical needed to achieve 20 mg / kg injection volume of 0.5 ml, ie 0.23241 g, which was dissolved in an appropriate volume of normal saline (NaCl 9%), with pH set at 6.5 with 1% sodium hydroxide (NaOH 1%). Next, we tried to obtain a pure solution by passing through a polymer of 0.45 μ m filter (Millipore), after which it was immediately injected. The scarification of the animals by poisoning the air, was performed at 28 weeks, as scheduled. At autopsy, all regions that corresponded with tumor lesions were recorded graphically, as the large intestine was divided into three equal segments (I = proximal, II = medium, III = distal), depending on the distribution.



Figure 1 - Appearance of macroscopic colorectal malignant lesions induced in mice with DMH after 12 weeks

RESULTS AND DISCUSSION

Under a bilateral test of mean difference and variation, we can say that, at a value of 5%, there was no difference between the average numbers of malignancies in the three segments examined. As neoplasia type I met an average of 5.143 for benign lesions, with a variable of 4.132 (between 2 and 8 tumors), and an average value of 3.571 malignant lesions, with a variable of 1.802 (from 2 to 6 tumors).

One of the animals died before the time fixed for the experiment was replaced with one another to maintain the number proposed for the analysis. This protocol resulted in tumor induction following numerical expression and regional incidence of neoplasia which we called a tumor percentage. In segment I met 27.1 percent (from 0 to 4 cancer, an average of 2.357, and a variable 1.3336) in segment II, 37.7% (from 1 to 6 cancer, an average of 3.286, and a variable 3.297), and in segment III, 35.2% of injuries (from 1 to 6 cancer, with an average of 3.071 and a variable 1.61). (Table 1)

Table 1

Percentage tumor intestinal segments			
Segments/Tumor	%	÷	(SD)
I (Proximal)	27,1	2,357	(1,333)
II (Mediu)	37,7	3,286	(3,297)
III (Distal)	35,2	3,071	(1,61)

% = Percent; ÷ = Mean (SD) = variable

According to a bilateral test of mean difference and variation, we can say that, at a value of 5%, there was no difference between the average number of malignancies in the three segments examined. As neoplasia type I met an average of 5.143 for benign lesions, with a variable of 4.132 (between 2 and 8 tumors), and an average value of 3.571 malignant lesions, with a variable of 1.802 (from 2 to 6 tumors) (see Fig. 2 and Fig. 3).

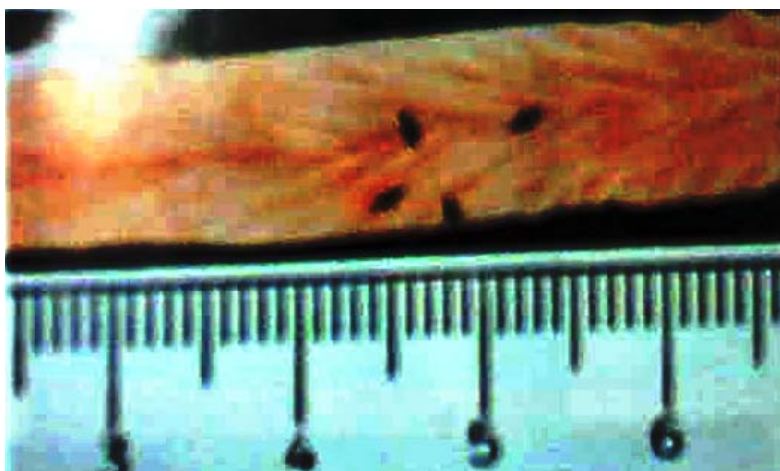


Figure 2 - The appearance of intestinal mucosa corresponding focal severe dysplasia histologically.



Figure 3 - The appearance of focal intestinal mucosal histology corresponding initial carcinoma without achieving its muscle.

Making a difference in average test and bilateral variables, we can say that, at a value of 5%, there was no difference between the average number of benign and malignant tumors.

CONCLUSIONS

The results, in this experimental model, show that tumor induction with DMH for a period of only 12 weeks in the conditions described, determines the appearance of colorectal epithelial tumors, benign and malignant conditions.

REFERENCES

1. Gregorcyk S. [The Current Status of the Acticon® Neosphincter](#). Clinics in Colon and Rectal Surgery, 2005 v.18 p32-37.
2. Lehur PA, Glemain P, Bruley des Varannes S, Buzelin JM, Leborgne J. Outcome of Patients With an Implanted Artificial Anal Sphincter for Severe Fecal Incontinence. A Single Institute Report. Int J Colorect Dis, 1998 v.13 p88-92
3. Vaizey CJ, Kamm MA, Gold DM, Bartram CI, Halligan S, Nicholls RJ. Clinical, physiological, and radiological study of a new purpose-designed artificial bowel sphincter. Lancet, Jul. 11, 1998 v.352 (9122) p105-109
4. Lehur PA, Michot F, Denis P, Grise P, Leborgne J, Teniere P, Buzelin JM. Results of artificial sphincter in severe anal incontinence. Report of 14 Consecutive Implantations. Diseases of the Colon and Rectum, 1996 v. 39 (12) p1352
5. Wong WD, Jensen LL, Bartolo DCC, Rothenberger DA. Artificial anal sphincter. Diseases of the Colon and Rectum, 1996 v.39(12) p1345-1351
6. Michot F. Artificial anal sphincter. 8th World Congress of International Gastro-surgical Club, 15-18 Apr. 1998 p767-773
7. Roberts RO, Jacobsen SJ, Reilly WT, Pemberton JH, Lieber MM, Talley NJ. Prevalence of Combined Fecal and Urinary Incontinence: A Community-Based Study, J of the American Geriatrics Society, July 1999 v.47 p.837-841
8. Christiansen J, Rasmussen O, Lindorff-Larsen K. Long-Term Results of Artificial Anal Sphincter Implantation for Severe Anal Incontinence, Annals of Surgery, 1999 v.230 p45-48
9. Wong WD, Congliosi SM, Spencer MP. The Safety and Efficacy of the Artificial Bowel Sphincter for Fecal Incontinence, Colon and Rectum, 2002 v.45 (9) p1139