

SURGICAL TREATMENT OF A DIFFUSE ANEURYSMAL DISEASE

Pop Adrian*, Jerzicska Erno, Dorobantu Cătălin, Dasmuth Nitish

*Facultatea de Medicină și Farmacie Oradea Piata 1 Decembrie, Nr.10, apop39@gmail.com

Abstract

Multiple aneurysms in a single patient are a situation with very low incidence. Such cases are possible in pathologies where the basis is collagen tissue damage. In collagen diseases, vascular damage may be multiple, from the dissecting aneurysms, varicose disease, hemorrhoid disease.

Key words: Aneurysm, collagen, angio-CT, bypass, Dacron prosthesis.

INTRODUCTION

We present a patient aged 26 years old who seeks medical help first time for the pain his left inguinal region which appeared after minimal physical effort. Clinical examination reveals a throbbing tumor formation in the left inguinal area. Due to lack of vascular surgery department in the town, the patient is referred from the emergency department to cardiology section for consultation. Vascular ultrasound examination reveals a common femoral artery aneurysm partially thrombosed. The patient is referred to a vascular surgery consultation.

MATERIAL AND METHODS

At the vascular surgical consultation patient complains mainly of claudicative pain in the left leg at 100 m. Please note that the patient is not a smoker or sedentary and does not have other associated disorders. A CT angiography with contrast showed an abdominal aortic aneurysm with a diameter of 4.2 cm, bilateral common iliac artery aneurysms 3.6 and 3.8 cm respectively (fig.1-2).

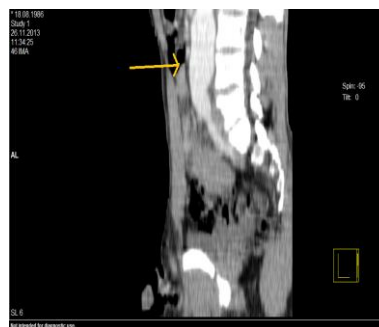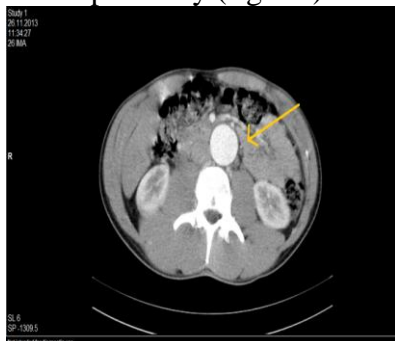


Fig.1 Abdominal aortic aneurysm 4.2cm

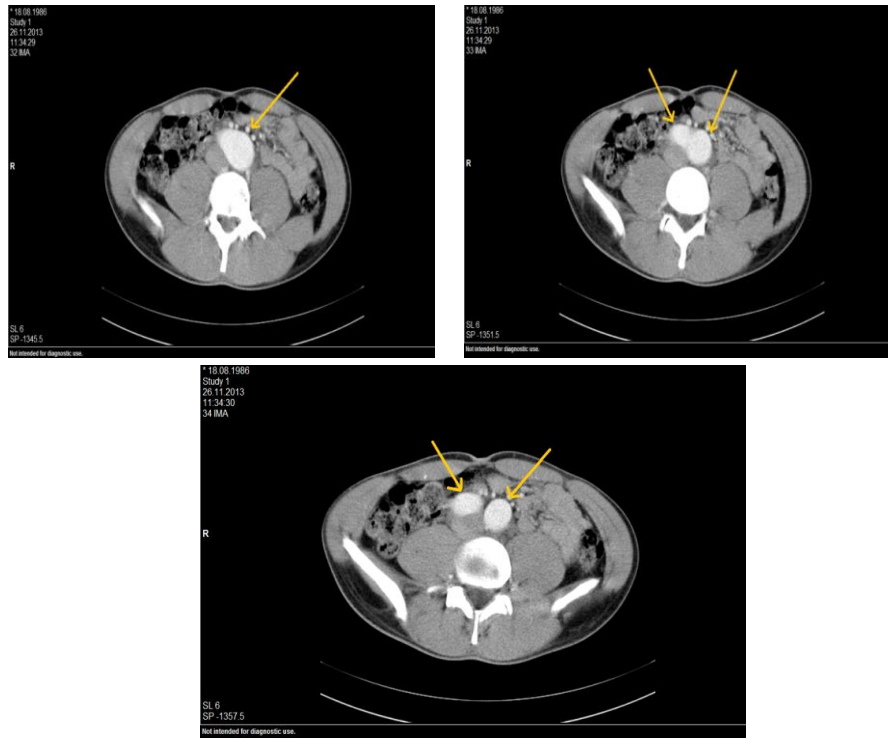


Fig.2 Aneurysm of common iliac artery bilateral

In the left common femoral artery an aneurysmal dilation of 4.8cm located between the left inguinal ligament and left common femoral artery bifurcation is observed (fig.3).

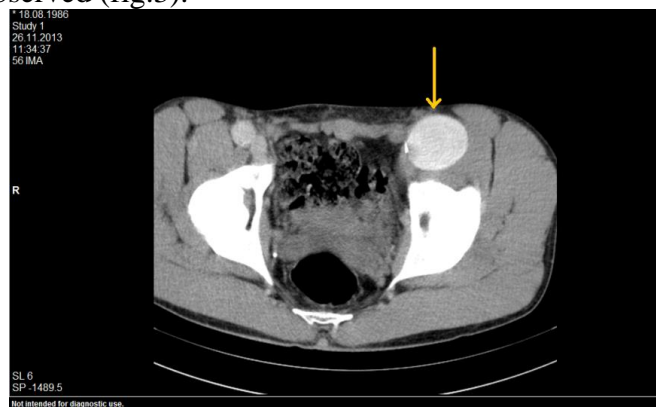


Fig. 3 Aneurysm of left common femoral artery

Moreover in the left popliteal artery an aneurysmal expansion with partial thrombosis and occlusion of the left tibioperoneal trunk is noticed. Popliteal artery aneurysm diameter is 4.2 cm and includes segments P 1 and P 2.

Patient also shows aneurysm of the common femoral artery and the right popliteal artery with no signs of intraluminal thrombosis. In plus, examination of the internal carotid arteries reveals ectasia of the internal carotid arteries bilaterally, but with diameter not exceeding 3 cm.

The patient is again referred for cardiology department but this time for echocardiography, where the intrapericardial ascending aorta diameter is found to be 4.1cm. The aortic valve is tricuspid, competent, sino-tubular junction is not dilated, LV ejection fraction 65%.

The patient was immediately referred for surgical procedure where left leg revascularization was performed, through a femoral-popliteal bypass using reversed autologous saphenous vein graft, selective thrombectomy of anterior and posterior tibial artery, ligation of the popliteal artery below the aneurysmal dilation, recalibration of left common femoral artery.

Postoperative evolution was good, but after 3 weeks a decrease flow rate of the posterior tibial artery was measured using the Doppler ultrasound, with persistence of the velocimetric aspect of the anterior tibial artery. Patient had no intermittent claudication.

In a second step surgery is carried out for complex reconstruction of infrarenal aorta where a partial resection of the abdominal aortic aneurysm, common iliac artery, and common femoral artery is performed with aortobifemoral bypass using Dacron prosthesis, reimplantation of the inferior mesentery artery and internal iliac arteries (fig.4).

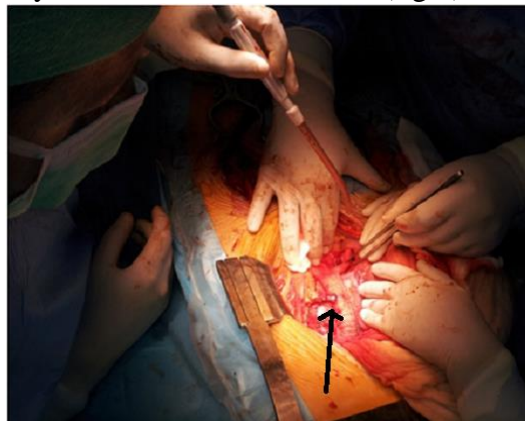

Fig.4 Aortobifemoral bypass using Dacron prosthesis, reimplantation of the inferior mesentery artery

RESULTS AND DISCUSSION

Postoperative evolution is favorable, with wound healing per primam. No postoperative erectile disorders. Surgical treatment of right popliteal artery aneurysm is temporarily delayed.

Complex reconstruction of the infrarenal aorta was mandatory, in order to diminish the risk of rupture and secondary thrombosis. No touch surgery at the level of presacral plane, reimplantation of both internal iliac arteries were performed to preserve genital function in a young male adult.

Anastomoses were performed in a termino-terminal manner. This technical variation was used to best preserve diameters of native arteries around anastomoses.

The key to success in this patients is close monitoring of target arteries at 6 months and treatment in uncomplicated phases of the evolution of the disease.

The underlying pathology is collagen tissue disease.

We monitor the patencies of existing bypasses, diameter and secondary thrombosis in the right popliteal artery, thoracic aorta both ascending and descending, internal carotid arteries.

CONCLUSION

Diffuse aneurysmal disease is a rare disorder, especially involving so much arterial sites. There is no known pathophysiologic treatment for the underlying connective tissue disease.

Surgery of the aneurysms and close monitoring is the way to preserve quality of life of this patient and prevent major and disabling complications of large and complicated aneurysms.

REFERENCES

1. Basnyat P. S., A. H. Biffin, L. G. Moseley, et al, 1999, Mortality from ruptured abdominal aortic aneurysm in Wales. *Br J Surg.* 1999 Jun; 86(6):765-70;
2. Baue A. E., A. S. Geha, G. L. Hammond, H. Laks, Naunheimks, 1996, Glenn's Thoracic and cardiovascular surgery, 6th edition, Vol. II, Appleton&lange, Stamford;
3. Braunwald E., D. P. Zipes, P. Libby, 2001, *Heart Disease: A textbook of Cardiovascular Medicine* ", 6th Edition, W. B. Saunders Company;
4. Cooley D. A., 1999, Aortic aneurysm operations: past, present, and future. *Ann Thorac Surg*;
5. Haimovici H., E. Ascer, L. Hollier, D. F. Stradness, J. B. Town, 1996, *Haimovici's Vascular Surgery. Principles and Techniques*", fourth Edition, Blavkwell Science;
6. Hallin A., D. Bergqvist, L. Holmberg, 2001, Literature review of surgical management of abdominal aortic aneurysm. *Eur J Vasc Endovasc Surg*;
7. Johnston K.W., R. B. Rutherford, M. D. Tilson, D. M. Shah, L. Hollier, J. C. Stanley, 1991, Suggested standards for reporting on arterial aneurysms: Subcommittee on Reporting Standards for Arterial Aneurysms, Ad Hoc Committee on Reporting Standards, Society for Vascular Surgery and North American Chapter, International Society for Cardiovascular Surgery. *J Vasc Surg*;
8. Pop D. I. Popa, 1982, *Sistemul arterial aortic. Patologie și tratament chirurgical*", Vol. I, Editura Medicală, București.
9. Raghavan M. L., D. A. Vorp, M. P. Federle, M. S. Makaroun, M. W. Websterv, 2000, Wall stress distribution on three-dimensionally reconstructed models of human abdominal aortic aneurysm. *J Vasc Surg*;
10. Socoteanu I., 2005, Note de curs. Chirurgie vasculară, UMF "Victor Babeș", Timișoara.